

AUTHORS: Kurz GH, Finaugler RB:

DATE: 1968

TITLE: Cataract secondary to microwave radiation.

SOURCE: Am J Ophthal 66:866-9

00032728

MAIN SUBJECT HEADING:

AN	<input checked="" type="radio"/> HU	AT	IH	M
ANALYTICS	HUMAN EFFECTS	ANIMAL TOXICITY	WORKPLACE PRACTICES- ENGINEERING CONTROLS	MISCELLANEOUS

SECONDARY SUBJECT HEADINGS: AN HU AT IH M

- | | |
|---------------------------------|--|
| Physical/Chemical Properties | Sampling/Analytical Methods |
| Review | Reported Ambient Levels |
| Animal Toxicology | Measured Methods |
| Non-occupational Human Exposure | Work Practices |
| Occupational Exposure | Engineering Controls |
| Epidemiology | Biological Monitoring |
| Standards | Methods of Analysis |
| Manufacturing | Treatment |
| Uses | Transportation/Handling/
Storage/Labeling |
| Reactions | |

MR 234

CATARACT SECONDARY TO MICROWAVE RADIATION

GEORGE H. KURZ, M.D. AND RICHARD B. EINAUGLER, M.D.
New York, N.Y.

It is well known that ionizing radiations may produce opacification of the crystalline lens. However, only a few cases of cataract allegedly secondary to microwaves have been reported in man. In this paper we report the clinical and histopathologic findings in a case of bilateral cataract in which the evidence strongly pointed to microwaves as the etiologic agent.




Fig. 1 (Kurz and Einaugler). Centrally located posterior subcapsular cataract in left eye of patient exposed to microwave radiation.

CASE HISTORY

The patient, a 51-year-old white man, described bilateral visual impairment of several years' duration. During a seven-year period he worked as a technical writer in electronic plants. In the course of his occupation he spent much time in the vicinity of microwave radiation and radiowave emitters. The patient did not recall ever having looked directly at the source of microwaves, and his exposure was not limited to radiation of any single wavelength.

Impairment of vision developed subsequent to the time of exposure. Lens extraction in each eye was performed eight years after last exposure. The patient had received no medications. His family history included a sister 10 years older than he who had been told that she had incipient cataracts. She was, however, not aware of any visual disturbance and not under the care of an ophthalmologist.

Clinical examination just prior to the lens extraction (fig. 1) revealed a dense, centrally located posterior subcapsular lens opacity in each eye with irregular projections extending toward the lens periphery. Visual acuity was 20/50- with best correction in each eye.

Both lenses were extracted intracapsularly and the postoperative visual result was 20/20 in each eye. The retina and optic nerve of each eye appeared normal postoperatively.

MICROSCOPIC EXAMINATION

Examination of the extracted left lens (fig. 2) revealed an intact capsule except for artifactual fragmentation. There were several areas in which the nuclei of the subcapsular epithelium were missing. The cortex immediately beneath the epithelium had degenerated (fig. 3). The nucleus was sclerotic. At the posterior pole, there was a large amount of degenerated cortex containing numerous globules

which appeared gray on routine hematoxylin- and eosin-stained sections (fig. 4). These globules contained birefringent material (fig. 5) and stained strongly positively for acid mucopolysaccharide with alcian blue and Hale's colloidal iron stain. Several epithelial cell nuclei were seen to have migrated beneath the posterior capsule in the region of the posterior pole. The remainder of the posterior subcapsular cortex showed minimal degeneration.

The right lens was inadvertently allowed to dry on a gauze sponge and its capsule was lost. In the superficial cortex there was degeneration, vacuolization and morgagnian globule formation. Multiple small gray patches similar to those observed in the left lens were scattered in the superficial cortical fibers in the posterior aspect of the lens, as seen in sections stained with hematoxylin and eosin. These patches were irregular in shape and size and contained fine irregularly arranged needlelike structures which were birefringent. They also stained positively for acid mucopolysaccharide.

COMMENT

Microwaves are shorter than short wave radio and longer than infrared, and have a wavelength between two millimeters and two meters. They are used in radar, microwave diathermy, long distance telephone systems, and television signals; their use is expanding into such areas as cooking, sterilization, and electrical power transmission.

In 1948 Richardson and co-workers¹ produced posterior cortical lens opacities in rab-

From the Department of Ophthalmology, New York University Medical Center. This study was supported in part by USPHS grants NB 05-059-05 and NB 05-002-13 from the National Institute of Neurological Diseases and Blindness.

Fig. 2 (Kurz and Einaugler). Left lens reveals nuclear sclerosis (N), degenerative changes beneath anterior capsule (A), and prominent area of degeneration at posterior pole (P). Lens capsule is artifactually fragmented. (PAS, $\times 13$.)

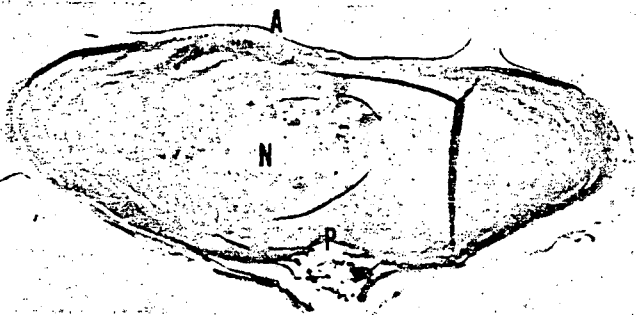


Fig. 3 (Kurz and Einaugler). Degenerative changes in anterior cortex (A). Note gaps in nuclei of subcapsular epithelium (arrows). (Hematoxylin-eosin, $\times 213$.)


bits three to nine days after direct single exposure to 12.25-cm microwaves. This exposure resulted in an average temperature of the vitreous at the posterior pole of the lens of 55.1°C .

The same authors² later reported changes of a different character produced in rabbit eyes by microwaves of 3-cm wave length (radar type). Superficial extraorbital tissue damage, corneal opacities, and opacities in the anterior segment of the lens were produced two to 60 days after exposure to the

shorter microwaves. The sites of damage for the different wavelengths corresponded with the location of maximum temperature elevation recorded in bovine eyes subjected to similar microwaves.

Daily and his associates³ summarized the two different types of experimentally induced microwave cataracts. The first type occurred immediately after exposure to microwaves and was seen only when grossly visible damage to other ocular structures was also produced, for example, corneal clouding

Fig. 4 (Kurz and Einaugler). Area of severe degeneration at posterior pole in which special stains revealed the presence of acid mucopolysaccharide. Posterior capsule (P). (Hematoxylin-eosin, $\times 83$.)



ATION
M.D.



ler). Centrally located
t in left eye of patient
ion.

antine hematoxylin- and
). These globules con-
(fig. 5) and stained
d mucopolysaccharide
s colloidal iron stain.
were seen to have mi-
capsule in the region
remainder of the poste-
ed minimal degenera-

tently allowed to dry
capsule was lost. In the
degeneration, vacuoli-
e formation. Multiple
those observed in the
e superficial cortical
of the lens, as seen in
ylin and eosin. These
pe and size and cong-
ged needlelike struc-
t. They also stained
saccharide.

T
than short wave
rared, and have a
millimeters and
ed in radar, mi-
distance telephone
signals; their use
areas as cooking,
power transmis-

co-workers¹ pro-
s opacities in rab-



Fig. 5 (Kurz and Einaugler)
Same area as in Figure 4, viewed
with polarized light. (Hematoxylin-
eosin, $\times 83$.)

and iris congestion. Here, diffuse subcapsular opacities were noted to coalesce rapidly to create a totally opaque lens. The second type of microwave cataract was not associated with obvious clinical signs of injury. This cataract appeared several days or weeks after microwave exposure and was confined to the posterior cortex. However, it also could progress to involve the entire lens if the eye were repeatedly exposed to microwaves.

Lerman⁴ pointed out a number of factors which explain the susceptibility of the lens to the thermogenic properties of microwaves. The lens is not only avascular, but its location 2 mm or more from any blood supply renders it less effective in dissipating heat than are most other organs. Daily and others⁵ demonstrated a reduction of lens enzymes in those rabbit eyes exposed to microwaves sufficient to cause visible damage to the lens.

While experiments have clearly revealed the ability of microwaves to produce cataracts in animals, in man the evidence is less clear-cut. Hirsch and Parker⁶ in 1952 reported the first case in a human being of cataracts attributed to microwave radiation. The patient was a 32-year-old male technician exposed to microwaves for six to eight hours a day for approximately one year. While making certain tests, it was necessary for him to look directly into an unshielded beam. This patient developed nuclear cata-

acts unlike the posterior cortical opacities produced experimentally.

Shimkovich and Shilyaev⁷ reported a case of a 22-year-old male technician in a radiocalization station who had multiple short exposures to high density microwaves of 10- to 12 cm-wavelength during a two-month period. One month later he noted a rapid decrease in visual acuity, and was found to have anterior and posterior cortical lenticular opacities in both eyes. In neither case were histopathologic findings reported.

Both of these cases followed exposure to microwave radiation levels significantly greater than those normally encountered in the occupational exposure of microwave workers. Cleary⁸ and Zaret⁹ and their co-workers in separate studies did not find lens changes in a sample of microwave workers to be significantly different from those exhibited by an unexposed control population. However, Zaret (Zaret, M. M.—oral communication, 1968) in a long-term study of 31 patients with a history of multiple occupational exposures to microwaves of varying wave lengths in the range of 1 to 10 cm, found streaking of the posterior lens capsule in all cases. In some this progressed to a cobweb or honeycomb appearance.

In the case presented here the most unusual feature is the localized area of degenerated cortex at the posterior pole of the lens which contained numerous globules with

VOL. 72
nuclei
mucop
on the
patholo
ract
Howev
latent
patient
case
indee

Bila
moved
eight
diatio
ologic
revea
the po
nucop
birefr

Hu

We
Fried

needlelike birefringent particles and acid mucopolysaccharide. We are unable to state on the basis of one case that these histopathologic findings are characteristic of cataract secondary to microwave radiation. However, the long history of exposure, the latent period, the relatively young age of the patient, and the absence of other ocular disease do suggest that the lens changes were indeed secondary to the microwave radiation.

SUMMARY

Bilateral subcapsular cataracts were removed from a 51-year-old technical writer eight years after exposure to microwave radiation over a seven-year period. Histopathologic examination of the extracted lenses revealed prominent areas of degeneration at the posterior pole containing globules of acid mucopolysaccharide and numerous, minute, birefringent needlelike structures.

*Hunterdon Medical Center
Flemington, New Jersey (08822)*

ACKNOWLEDGMENT

We wish to express our appreciation to Alan J. Friedman, M.D., who provided clinical information.

OPHTHALMIC MINIATURE

Case C.N., a painter and paper-hanger, from boyhood has been more or less troubled with weak eyes, had recently to work very much among green paper (flocked), and during which period his eyes were considerably worse; this he attributed to dust and other foreign particles getting into the eyes and causing them to be inflamed, being already predisposed to it. On requesting him to bring a portion of green paper, I found by a few chemical tests undoubted presence of arsenic in it, and had no hesitation in attributing the inflamed state of the eyes to it; this was confirmed by his speedy recovery after ceasing to work with the green paper.

*On the Preservation of Sight
By Angus MacMillan, M.D.
London, circa 1859*

REFERENCES

1. Richardson, A. W., Duane, T. D. and Hines, H. M.: Experimental lenticular opacities produced by microwave irradiations. *Arch. Phys. Med.* 29:765, 1948.
2. Richardson, A. W., Duane, T. D. and Hines, H. M.: Experimental cataract produced by three centimeter pulsed microwave irradiations. *Arch. Opth.* 45:382, 1951.
3. Daily, L., Wakim, K. G., Herrick, J. F., Parkhill, E. M. and Benedict, W. L.: The effects of microwave diathermy on the eye of the rabbit. *Am. J. Opth.* 35:1001, 1952.
4. Lerman, S.: *Cataracts—Chemistry, Mechanisms, and Therapy.* Springfield, Thomas, 1964, p. 128.
5. Daily, L. Jr., Zeller, E. A., Wakim, K. G., Herrick, J. F. and Benedict, W. L.: Influence of microwaves on certain enzyme systems in the lens of the eye. *Am. J. Opth.* 34:1301, 1951.
6. Hirsch, F. G. and Parker, J. T.: Bilateral lenticular opacities occurring in a technician operating a microwave generator. *Arch. Indust. Hyg. Occup. Med.* 6:512, 1952.
7. Shimkovich, I. S. and Shilyaev, V. G.: Cataract of both eyes which developed as a result of repeated short exposures to an electromagnetic field of high density. *Vestn. Oftal.* 72:12, 1959.
8. Cleary, S. F., Pasternack, B. S. and Beebe, G. W.: Cataract incidence in radar workers. *Arch. Environ. Health* 11:179, 1965.
9. Zaret, M. M., Cleary, S. F., Pasternack, B. S., Eisenbud, M. and Schmidt, H.: A study of lenticular imperfections in the eyes of a sample of microwave workers and a control population. *RADC-TDR-63-125*, U. S. Air Force Document, March 1963.